

Chronic cerebrospinal venous insufficiency

Have we found the cause and cure of MS?



Robert J. Fox, MD
Alex Rae-Grant, MD

Address correspondence and reprint requests to Dr. Robert J. Fox, 9500 Euclid Avenue, Cleveland Clinic Foundation, Cleveland, OH 44195
foxr@ccf.org

Neurology® 2011;77:1

Multiple sclerosis (MS) has traditionally been considered an autoimmune disorder—an abnormal immune system attacking an otherwise healthy brain, spinal cord, or optic nerve. But even in its original description by Charcot, the perivenular predilection of MS lesions suggested a potential vascular etiology. In 1935, Tracy Putman¹ reported an animal model of MS based on injecting obstructing agents into the venous sinuses. On the basis of this model he treated 74 patients with MS with the anticoagulant dicumaryl, with mixed results.² After lying dormant for over half a century, the vascular theory of MS re-emerged with a series of publications led by the Italian vascular surgeon Paolo Zamboni. He used ultrasound and catheter-based venography to describe venous insufficiency in the internal jugular veins (IJV), vertebral veins, and deep cerebral veins of patients with MS, coining the term chronic cerebrospinal venous insufficiency (CCSVI).³ Five ultrasound criteria were proposed (figure), although these have yet to be validated against a criterion standard. Using these criteria, Zamboni and colleagues reported a surprisingly high 100% sensitivity and 100% specificity in discriminating patients with MS from controls. The same group reported clinical improvements in an open-label study of catheter-based venoplasty,⁴ later provocatively named the liberation procedure.

The public response to these reports was profound.⁵ Web sites, blogs, Facebook pages, and other social network media promoted the CCSVI theory as salvation for patients with MS. Around the world, Web sites sprang up advertising treatments for CCSVI. In Canada, politicians debated whether to pay for testing and treatment for this condition. Some vascular surgeons treated CCSVI in patients with MS using endovascular stents, with reports of fatal consequences in 2 patients and near-fatal consequences in another.^{6,7} It became clear that the CCSVI theory went far beyond the traditional clinical research enterprise and had become a media-driven phenomenon.

Following the reports from Zamboni and colleagues, several other groups performed small CCSVI studies and came to different conclusions. One study evaluated 56 patients with MS and 20 controls using ultrasound and found that none met criteria for CCSVI.⁸ Another study evaluated 21 patients with MS and 20 controls with phase-contrast magnetic resonance angiography and found no difference in IJV outflow or the presence of IJV reflux between patients with MS and controls.⁹ These results challenged the hypothesis that CCSVI plays a role in MS. Furthermore, CCSVI does not explain the genetic, ethnic, or geographic preferential occurrence of MS, although CCSVI has not been studied in relation to these factors.

In this issue of *Neurology*®, Zivadinov and colleagues¹⁰ report the results of the largest CCSVI study to date. Using a single, unblinded ultrasound technician who studied 499 subjects, they found that 56% of patients with MS met criteria for CCSVI, as did 23% of healthy controls and 46% of subjects with other neurologic diseases. A post hoc analysis suggested that CCSVI was more prevalent in progressive MS than relapsing forms of MS. Together, these observations demonstrate an increased prevalence of CCSVI in patients with MS, but with a considerably lower prevalence than reported by Zamboni et al. and with substantial proportions of healthy controls and patients with other diseases demonstrating the same ultrasound changes.

This study suggests that CCSVI, as defined using ultrasound of the intracranial and extracranial venous system, is not likely to be a primary causal process in MS. An increased prevalence in progressive as compared with relapsing disease leaves open the possibility that CCSVI may be playing a contributory role in, or be a consequence of, the disease, or may be age-related.

Where do we go from here? Several issues need to be addressed in order to move forward. Many facets

See page XXX

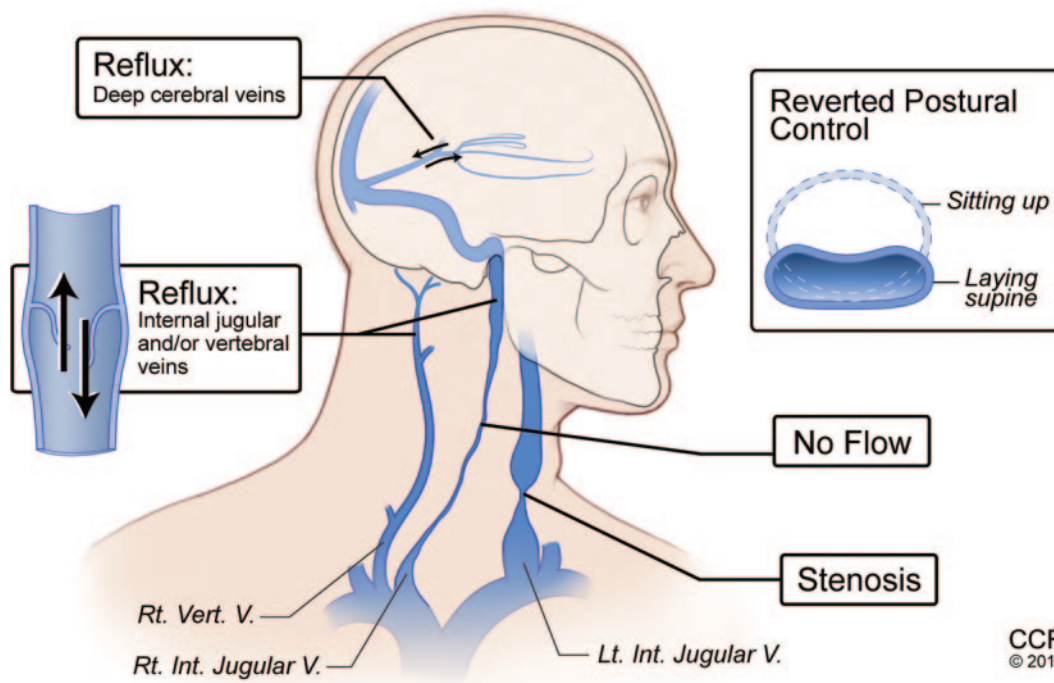
e-Pub ahead of print on April 13, 2011, at www.neurology.org.

From the Mellen Center for Multiple Sclerosis, Neurological Institute, Cleveland Clinic Lerner College of Medicine, Cleveland Clinic, Cleveland, OH.

Study funding: Supported by RC 1004-A-5 and RG 4103A4/2 from the National MS Society.

Disclosure: Author disclosures are provided at the end of the editorial.

Figure Illustration of the vascular abnormalities comprising the proposed entity chronic cerebrospinal venous insufficiency



The 5 boxes describe the 5 abnormalities included in the proposed ultrasound diagnostic criteria.³ Reprinted with permission, Cleveland Clinic Center for Medical Art & Photography © 2010. All rights reserved.

of CCSVI ultrasound studies are untested or unclear. The within-rater, between-rater, and cross-center reproducibility and the effects of hydration are unknown. The relationship between ultrasound findings and both normal anatomic variation and true venous insufficiency is not well-understood. Validated magnetic resonance venography criteria for CCSVI are lacking. The relationship between CCSVI and other aspects of MS is unknown, including MRI measures, disease duration, and disease progression. Pathologic evaluation of cervical and azygous veins is needed to understand the histologic correlates of ultrasound-defined CCSVI.

To help address the conflicting reports, in June 2010 the United States and Canadian Multiple Sclerosis Societies awarded 7 research awards totaling \$2.4 million to study CCSVI. Together, these projects will evaluate over 500 patients with MS and 600 controls using ultrasound, magnetic resonance angiography, catheter-based venography, and pathologic studies from autopsy tissue. In addition, the Canadian Institutes of Health Research commissioned a standing Scientific Expert Working Group to monitor and analyze results from these and other ongoing CCSVI studies. Given the uncertainties of the relationship between CCSVI and MS and the potential risks of intervention, any CCSVI intervention such as balloon venoplasty should be restricted

to a blinded, controlled clinical trial using carefully chosen clinical endpoints and appropriate patient safety oversight.

It behooves the clinical research community to carefully pursue CCSVI to its end; we should neither jump on the bandwagon as it passes through town, nor assiduously miss the parade. If CCSVI is a useful clinical or research endeavor for some proportion of the MS population, we should acknowledge its importance. If CCSVI is not found to be linked to MS, efficient and definitive studies will let us redirect precious resources toward research efforts more likely to advance the understanding and treatment of this disease.

ACKNOWLEDGMENT

The authors thank Drs. Jeffrey Cohen and Richard Rudick, Cleveland Clinic, for their discussion and review of this manuscript.

DISCLOSURE

Dr. Fox has received speaker honoraria from Biogen Idec and Teva Pharmaceutical Industries Ltd.; has served as a consultant for Biogen Idec, Genentech, Inc., and Novartis; has served on clinical trial advisory committees for Biogen Idec; has received/receives research support from the National Multiple Sclerosis Society (RG 4091A3/1; RG 4103A4/2; RC 1004-A-5), which includes funding to study CCSVI; and serves on the editorial boards of *Neurology*[®] and *Multiple Sclerosis*. Dr. Rae-Grant has received speaker honoraria from Biogen Idec, EMD Serono, Inc., and Teva Pharmaceutical Industries Ltd.; receives publishing royalties for *Handbook of Multiple Sclerosis* (Springer Healthcare, 2010); serves on the

speakers' bureau of Biogen Idec; and has received research support from the National Multiple Sclerosis Society (RC 1004-A-5).

REFERENCES

1. Putman TJ. Studies in multiple sclerosis: IV: "encephalitis" and sclerotic plaques produced by venular obstruction. *Arch Neurol Psychiatry* 1935;33:929–940.
2. Putnam TJ, Chiavacci LV, Hoff H, Weitzen HG. Results of treatment of multiple sclerosis with dicoumarin. *Arch Neurol Psychiatry* 1947;57:1–13.
3. Zamboni P, Galeotti R, Menegatti E, et al. Chronic cerebrospinal venous insufficiency in patients with multiple sclerosis. *J Neurol Neurosurg Psychiatry* 2009;80:392–399.
4. Zamboni P, Galeotti R, Menegatti E, et al. A prospective open-label study of endovascular treatment of chronic cerebrospinal venous insufficiency. *J Vasc Surg* 2009;50:1348–1358.
5. Grady D. From M.S. patients, outcry for unproved treatment. *New York Times*. June 29, 2010:D1.
6. Samson K. Experimental multiple sclerosis vascular shunting procedure halted at Stanford. *Ann Neurol* 2010;67:A13–5.
7. Ontario man dies after MS vein opening. *CBC News*. 2010. Available at: <http://www.cbc.ca/health/story/2010/11/18/multiple-sclerosis-vein-death-costa-rica-mostic.html>. Accessed February 4, 2011.
8. Doepp F, Paul F, Valdueza JM, Schmierer K, Schreiber SJ. No cerebrocervical venous congestion in patients with multiple sclerosis. *Ann Neurol* 2010;68:173–183.
9. Sundstrom P, Wahlin A, Ambarki K, Birgander R, Eklund A, Malm J. Venous and cerebrospinal fluid flow in multiple sclerosis: a case-control study. *Ann Neurol* 2010;68:255–259.
10. Zivadinov R, Marr K, Cutter G, et al. Prevalence, sensitivity, and specificity of chronic cerebrospinal venous insufficiency in MS. *Neurology* 2011;77:XXX–XXX.